

---

# ANESTHESIOLOGY 2012

---

TRANSFORMING PATIENT SAFETY THROUGH EDUCATION AND ADVOCACY

## Cancer Pain: State of the Art 2012 ASA Meeting

Allen W. Burton, M.D.

Houston, Texas

### Introduction:

“We don’t beat the Reaper by living longer. We beat the Reaper by living well.” Professor Randy Pausch declared this statement during his famous last lecture at Carnegie Mellon University prior to his death from pancreatic cancer in 2008. (Pausch 2008) As opposed to the widely utilized WHO approach of utilizing opioids first, many now advocate a mechanism based approach to cancer pain treatment. Old dogma treated cancer pain as a problem mainly toward the end of life situation in the context of metastatic, progressive disease, whereas new data shows pain to be problematic throughout the cancer care cycle. (Ahmedzai 2007) The effective management of these acutely painful surgeries and related treatments may limit the development of chronic pain states in long-term survivors.(Burton 2007) Effective treatment strategies include multidisciplinary, multimodal care utilizing: (1) combinations of long acting opioids for constant pain with short acting opioids for incidental pain; (2) ‘adjuvant’ co-analgesics including non-steroidal anti-inflammatories, anticonvulsants, antidepressants, and topical agents to optimize analgesia and minimize opioid doses thereby reducing concomitant opioid related side effects; (3) prophylactic treatment of constipation, nausea, and other common troublesome symptoms;(4) interventional options for pain control including: nerve blocks, spinal infusions, vertebral augmentation, and other procedures. Lastly (5), psychological evaluation and support must not be overlooked. This monograph will focus on the role of procedures in context of the overall cancer treatment and in the overall context of palliative care. Traditional analgesic procedures will be discussed in addition to briefly highlighting neurodestructive procedures, vertebro and kyphoplasty, fracture stabilization, tumor ablation, and others. Finally, the decision making relating to the role, timing, and special risks of procedures in the cancer patient will be highlighted. This monograph is devoted to the science and decision making aspects of interventional cancer pain techniques; for a “how” to do it approach, the interested reader is directed to either Rathmell or Brown’s excellent atlas’ of interventional pain procedures. (Rathmell JP 2006, Brown DL 2006)

### Decision Making:

In traditional pain management teachings, several arbitrary distinctions are usually created. Cancer pain, chronic pain (so called “non-malignant” pain), and acute pain are viewed as distinct clinical entities with unique treatment strategies. In fact, these distinct clinical entities represent slightly different aspects of common pathophysiologic states which blend together in a disease continuum. Therefore, there is much overlap in appropriate therapeutic approaches to “cancer pain.” For example, optimal acute pain management for cancer surgery may be important to the patient’s overall outcome in the avoidance of chronic pain and perhaps even improved survival. (Vila 2007)

When considering the need for procedural intervention in the patient with progressive cancer, the decision making algorithm is complex, but generally comes down to a decision algorithm which includes failure to achieve adequate pain relief through pharmacological means and pain anatomically susceptible to an intervention. (Swarm 2007) These issues usually generate a referral to an interventionalist, often-but not necessarily-an anesthesiologist. Often, patient’s pharmacologic options have been exhausted and the referral for an intervention occurs very far along in their disease process, essentially at the very end stages of life. However, this traditional approach-the WHO tier ladder, placing interventions on the fourth step is not always in the patient’s best interest. (Ahmedzai SH 2007, Burton 2007) In many cases of localized, severe pain-the risk and benefit ratio swings in favor of an interventional pain relieving procedure well prior to exhausting the pharmacological approaches. Typically, the procedure will not substitute for the ongoing use of other pain control modalities entirely, but can improve pain relief and allow for a

Refresher Course Lectures Anesthesiology 2012 © American Society of Anesthesiologists. All rights reserved.

Note: This publication contains material copyrighted by others. Individual refresher course lectures are reprinted by ASA with permission. Reprinting or using individual refresher course lectures contained herein is strictly prohibited without permission from the authors/copyright holders.

---

# ANESTHESIOLOGY 2012

---

TRANSFORMING PATIENT SAFETY THROUGH EDUCATION AND ADVOCACY

reduction in systemic medications and their side effects. The interventional specialist must determine if a procedure is likely to provide tangible benefit and ensure there is no contraindication to the procedure (ie- pancytopenia, hemodynamic instability, etc.). Finally, especially in terms of spinal infusions, advanced planning for home care and appropriate follow-up care is critical. (Mercadante 1994)

## **Spinal Infusions:**

Two broad groups of patients, those with poor pain relief in spite of numerous analgesic trials and those with unacceptable side effects from analgesics may benefit from neuraxial analgesic infusions. (Crul 1991, Smith 2002, Burton 2004, Smith 2005) There have been many reports of successful analgesia with epidural and intrathecal infusion. In our center, we have moved almost exclusively to the intrathecal route (except in the immediate postoperative period) (Burton 2004). The reason for favoring the intrathecal route is economic; we have seen similar analgesia with much lower infusion rates/volumes- whereas the epidural infusion regularly uses 10 or more cc's per hour, the intrathecal usually runs at 0.5 cc's per hour- saving numerous resources in addition to having to change external bags much less often. The clinical equivalence of the intrathecal and epidural routes has been confirmed by other groups. (Mercadante 2008) Neuraxial infusions can be implemented in a variety of ways and with various medications and equipment as outlined below.

In patients with progressive disease and a short survival time, a percutaneous catheter, portacath, "DuPens" percutaneous catheter, or tunneled "epidural" catheter (usually placed in the intrathecal space) with an external pump may be most cost effective, and most easily adjustable in the home care setting. (Crul 1991) Recent meta-analysis of complications related to home, external intrathecal catheters reveals a low rate of serious complications. The rate of superficial infection was 2.3%, deep infection 1.4%, with the authors calculating that every 71<sup>st</sup> patient had a deep infection after 54 days of therapy, with the risk of bleeding and neurological injury 0.9% and 0.4% respectively. (Aprili 2009) Therefore, in cancer pain patients with a short life expectancy, with adequate home resources, and external intrathecal catheter can be considered an effective and low-cost option. One decision making algorithm published by our group is shown in figure 1. (Phan 2005)

Patients being considered for an implanted pain pump will need a trial infusion in many ways similar to the external infusion described above. Issues around pump implantation and management are covered in a nice "how we do it" article by Smith and Coyne. (Smith 2003) These patients will generally have a longer life expectancy or in some cases chronic cancer pain in a non-terminal setting. The optimal medication for infusion is a matter for a longer monograph, however expert poly-analgesic recommendations exist and have been recently updated. (Deer 2007) In terms of chronic versus cancer pain, the main difference is a more rapid, aggressive dose and drug titration in the cancer patients. In our center, our preferred first line is often hydromorphone alone or in combination with bupivacaine. In refractory cases, ziconotide may be added or substituted as a potent non-opioid neuraxial analgesic. (Rauck 2009)

## **Other Cancer Analgesic Procedures:**

Vertebroplasty (VP) is the injection of a painful, fractured vertebral body with bone cement, generally polymethylmethacrylate (PMMA). Kyphoplasty (KP) adds the placement of balloons into the vertebral body with an inflation/deflation sequence to create a cavity and perhaps restore height prior to the cement injection. These procedures are performed in a percutaneous fashion on an outpatient (or short stay) basis, usually with monitored anesthesia care/heavy sedation. The mechanism of action is unknown, but is postulated that stabilization of the fracture leads to analgesia.

The procedure is indicated for painful vertebral compression fractures due to osteoporosis or malignancy. The ideal candidate has severe axial (non-radiating) pain due to a fractured vertebrae. Patients failing a short course of conservative therapy, including analgesics and bracing, are generally considered good candidates for one of these procedures. Patients with painful fractures more than one year old are not likely to obtain substantial benefit from VP or KP, unless there is evidence of a fracture non-union (such as edema on MRI or a positive bone scan). Pain relief is seen in around two-thirds of patients, and even those with advanced disease may find significant

---

# ANESTHESIOLOGY 2012

---

TRANSFORMING PATIENT SAFETY THROUGH EDUCATION AND ADVOCACY

improvement in quality of life. (Fourney 2003, Hentschel 2005, Burton 2005) In patients with advanced metastatic disease, these procedures can be combined with local tumor ablation and/or sequenced with spinal radiation therapy as needed. (Georgy 2009) Finally, patients with painful spinal metastasis and neurological compromise may be candidates for spinal surgery up to and including vertebrectomy which in many cases provides significant improvement in quality of life and may increase lifespan as well. (Choi 2009)

### Tumor Ablation (Radiofrequency/Cryoablation)/Cementoplasty:

Local tumor ablation with or without addition of bone cement is a recent addition to the cancer pain treatment armamentarium. Several studies show favorable local pain relief following tumor ablation. Studies are underway to determine which technique is optimal (Callstrom 2002). When a fracture is impending due to extensive lytic involvement, then bone cement may be injected into this void created by the tumor ablation. This is often done in the hip, femur, and pelvis. (Munk 2009)

### Neurosurgical ablative:

In some cases of pain refractory to aforementioned techniques, including spinal analgesic infusion, ablative neurosurgical techniques may be useful. Overall, the use of these techniques has dropped precipitously over the years-presumably as other effective pain control therapies have been implemented. In many centers, it can be difficult to find the local neurosurgical expertise to perform some of these procedures. The most commonly used procedures include anterolateral cordotomy for lateralized pain, midline myelotomy for pelvic pain, rhizotomy and/or dorsal root entry zone lesioning for plexopathic pain, and finally various ablative procedures used in the past include pituitary ablation for bone pain, and others. Many authors and centers, particularly outside of the US, view the cordotomy as a valuable technique in managing refractory cancer pain. (Raslan 2008) Techniques mainly used experimentally or in chronic pain states include deep brain stimulation or cortical stimulation. (Fenstermaker 1999)

### Surgical:

In many pathologic cancer pain states, surgical techniques may be highly effective as palliative techniques. These include vertebrectomy for metastatic disease in selected cases-as mentioned earlier in this paper, fixation of pathologically fractured long bones. (Choi 2009) Viscerally, placement of venting gastrostomy and feeding jejunostomy tubes, or diverting ostomies may provide effective palliation of visceral symptoms associated with gastric outlet obstruction. (Easson 2007) Other shunting procedures may be helpful with malignant pleural effusions or ascites. More recently, a variety of less invasive stenting procedures have been developed for the bronchus, esophagus, and many hollow viscera. (Sharma 2009)

### Neurolytic Blocks

In many cases, clinicians may wish to, where feasible, perform a "test block" with local anesthetic to ensure that the patient obtains analgesia from the block and does not find the sensory changes uncomfortable. (Lamacraft 1997) Unfortunately, the down side of a "test block" is that the amount of pain relief obtained with the neurolytic block may fall short of that achieved with the local anesthetic block.

With head and neck cancers, the pain is often diffuse and crossing tissue planes/nerve distributions making the role of neurolytic blocks limited. Some patients will have focal pains that are amenable to the following blocks: peripheral trigeminal (ie- supraorbital, mental), trigeminal, sphenopalatine, glossopharyngeal, occipital and superficial cervical plexus. (Varghese 2002)

Visceral pain has a discrete innervation which makes it amenable to neurolytic blockade. For upper abdominal pain associated with pancreatic, liver, or gastric tumor the celiac plexus block has been advocated. Numerous approaches and medications have been tried and compared in the literature with good support for favorable clinical outcomes in more than two-thirds of patients undergoing the block (Eisenberg 1995). In our center, we use a posterior approach guided by fluoroscopy, with two needles placed in the retrocrural space. We inject local anesthetic followed by 50-100% alcohol or 8-10% phenol solution up to 20 cc's volume. Other approaches that have been advocated include transgastric via an endoscope and anterior with ultrasound guidance (Moore 2009, Burton 2009). The anterior approach with ultrasound is very exciting for potential application at the bedside in a hospice setting. (Bhatnagar 2008) The majority of patients undergoing celiac block will experience

# ANESTHESIOLOGY 2012

TRANSFORMING PATIENT SAFETY THROUGH EDUCATION AND ADVOCACY

orthostatic hypotension due to visceral vasodilatation and diarrhea due to unopposed parasympathetic effect. Neurologically, there is a small risk of paraplegia. (Davies 1993)

For pain in the pelvic viscera, the superior hypogastric, more recently the inferior hypogastric plexus block, and the Ganglion Impar block have been described and utilized-although not as widely as the celiac block (Plancarte 1997, Schultz 2007). The superior hypogastric block should cover pain coming from the bladder, uterus, vagina, prostate, urethra, testes, descending colon, and rectum. An anterior approach has also been described for patients who cannot lie prone. (Mishra 2008) The inferior hypogastric plexus lies anterior to the sacrum at approximately the S2 level, and may provide pain relief for rectal pain according to recent case reports. The Ganglion of Impar lies just anterior to the sacrococcygeal junction and is easily blocked with an injection just anterior to the sacrum. This procedure often provides pain relief for perineal pain without risk of incontinence. (Plancarte 1997)

Risks of neurolytic blocks nearly always include deafferentation pain, which is the main reason neurolytic blockade is not used in the chronic pain setting. Further, with the celiac plexus block there is a risk of paralysis-probably due to anterior spinal artery vasospasm and infarct. With the hypogastric plexus block, we have seen several cases of lower extremity hip flexor weakness due to inadvertent spread of neurolytic agent to the psoas muscle with a partial denervation of the lumbar plexus (unpublished data). We have modified our technique to ensure medial needle placement and medial dye spread prior to neurolytic injection. As neurolytic blocks are relatively rare, the incidence of complication is difficult to determine, but weakness or paralysis are felt to occur with less than 5% incidence and perhaps less than 1%, although they clearly are reserved for the patient with progressive cancer and refractory pain.

Other special circumstances include neurolysis of peripheral nerves including the intercostals or other peripheral branches. Intercostal neurolysis can produce short term relief, with one author finding a median duration of effect to be three weeks, although in their series of 25 patients one-third had analgesia until the end of life. (Wong 2007) These authors found optimal outcomes using a diagnostic block, followed by a 10% phenol injection in those obtaining relief with the diagnostic block.

Subarachnoid or epidural neurolysis has been done in highly refractory cases where bladder and bowel function are already compromised. Slatkin reported four cases of phenol saddle blocks with reasonably good outcomes, with the use of 0.6-1 ml of 6% phenol in glycerin injected via subarachnoid injection in cases of highly refractory pelvic cancer pain. (Slatkin 2003) This report also nicely reviews the literature.

Neurolytic blocks are often extremely helpful in patients with advanced cancer, debilitation, and severe, refractory pain syndromes.

## **Conclusions**

As opposed to the automatic WHO approach of utilizing opioids first, many now advocate a mechanism based approach to cancer pain treatment. Old dogma relegated cancer pain as a problem toward the end of life situation with metastatic, progressive disease, whereas new data shows pain to be problematic throughout the cancer care cycle. The effective management of these acutely painful surgeries and related treatments may limit the development of chronic pain states in long-term survivors. Effective treatment strategies include multidisciplinary, multimodal care utilizing: (1) combinations of long acting opioids for constant pain with short acting opioids for incidental pain; (2) 'adjuvant' co-analgesics including NSAIDS, anticonvulsants, antidepressants, and topicals to minimize opioid doses and concomitant opioid related side effects; (3) prophylactic treatment of constipation, nausea, and other symptoms; (4) interventional options for pain control including: nerve blocks, parenteral infusions, spinal infusions, palliative XRT, palliative chemotherapy, psychological assessment with support, and surgery in combination for optimal patient quality of life.

Finally, in cases of indolent cancer or remission, cancer pain syndromes effectively become chronic pain states in nearly all aspects. Thus, in these situations, optimal success will be seen through the use of chronic pain multidisciplinary assessment and treatment strategies. The goals of treatment in chronic post-cancer pain or "success" are slightly altered from the "Freedom from cancer pain" label above the WHO ladder to the more realistic: "Optimal functioning, optimal analgesia, and effective coping with ongoing pain."

---

# ANESTHESIOLOGY 2012

---

TRANSFORMING PATIENT SAFETY THROUGH EDUCATION AND ADVOCACY

This author views the WHO ladder concept as outdated and vastly oversimplified in 2010, and advocates a mechanism based use of all the above therapies in context of the patient's pain syndrome. More resource commitment to support ongoing research into unrelieved cancer pain is essential. (Brawley 2009)

## References

Ahmedzai SH, Boland J. The total challenge of cancer pain in supportive and palliative care. *Curr Opin Support Palliat Care* 2007;1(1):3-5.

Aprili D, Bandschapp O, Rochlitz C, Urwyler A, Ruppen W. Serious complications associated with external intrathecal catheters used in cancer pain patients. A systematic review and meta-analysis. *Anesthesiology* 2009;111:1346-55.

Bhatnagar S, Gupta D, Mishra S, Thulkar S, Chauhan H. Bedside ultrasound-guided celiac plexus neurolysis with bilateral paramedian needle entry technique can be an effective pain control technique in advanced upper abdominal cancer pain. *J Pall Med* 2008;11(9):1195-9.

Brawley OW, Smith DE, Kirch RA. Taking action to ease suffering: Advancing cancer pain control as a health care priority. *CA Cancer J Clin* 2009;59:285-89.

Brown DL. Atlas of Regional Anesthesia, Third Edition. Philadelphia, PA, Elsevier Saunders, 2006.

Burton AW, Rajagopal A, Shah HN, Mendoza T, Cleeland CS, Hassenbusch SJ, Arens JF. Epidural and Intrathecal Analgesia is Effective in Treating Refractory Cancer Pain. *Pain Medicine* 5(3):239-247, 2004.

Burton AW, Reddy SK, Shah HN, Tremont-Lukats I, Mendel E. Percutaneous vertebroplasty—a technique to treat refractory spinal pain in the setting of advanced metastatic disease: a case series. *J Pain Symptom Manage* 2005;30(1):87-95.

Burton AW, Fanciullo GJ, Beasley RD, Fisch MJ. Chronic pain in the cancer survivor: a new frontier. *Pain Med* 2007;8(2):189-98. Review.

Burton AW, Hamid B. Current challenges in cancer pain management: does the WHO ladder approach still have relevance? *Expert Rev Anticancer Ther* 2007;7(11):1501-2.

Burton AW. Celiac plexus blocks: wider application warranted for treating pancreatic cancer pain. *J Support Oncol* 2009;7(3):88-9.

Callstrom MR, Charboneau JW, Goetz MP, et al. Painful metastasis involving bone: feasibility of percutaneous CT- and US-guided radio-frequency ablation. *Radiology* 2002;224(1):87-97.

Choi D, Crackard A., Bunger C, et al. Review of metastatic spine tumour classification and indications for surgery : the consensus statement of the Global Spine Tumour Study Group. *Eur Spine J* 2009;e pub.

Crul BJ, Delhaas EM. Technical complications during long-term subarachnoid or epidural administration of morphine in terminally ill cancer patients: a review of 140 cases. *Reg Anesth* 1991;16(4):209-13.



---

# ANESTHESIOLOGY 2012

---

TRANSFORMING PATIENT SAFETY THROUGH EDUCATION AND ADVOCACY

Davies DD. Incidence of major complications of neurolytic celiac plexus block. *Journal of the Royal Society of Medicine*. 1993;86:264-66.

Deer T, Krames ES, Hassenbusch SJ, Burton AW, Caraway D, Du Pen S, Eisenach J, Erdek M, Grigsby E, Kim P, Levy R, et al. Polyanalgesic consensus conference 2007: Recommendations for the management of pain by intraspinal (intrathecal) drug delivery: Report of an expert interdisciplinary panel. *Neuromodulation* 2007;10(4):300-28.

Easson AM and Pisters PWT. The role of palliative surgery. *In Cancer Pain Management* (Fisch MJ and Burton AW Eds), McGraw Hill, New York, New York pp. 263-270, 2007.

Eisenberg E, Carr DB, Chalmers TC. Neurolytic celiac plexus block for treatment of cancer pain: a meta-analysis. *Anesth Analg* 1995;80:290-5.

Fenstermaker RA. Neurosurgical invasive techniques for cancer pain: A pain specialist's view. *Curr Rev Pain* 1999;3(3):190-7.

Fourney DR, Schomer DF, Nadar R, et al. Percutaneous vertebroplasty and kyphoplasty for painful vertebral body fractures in cancer patients. *J of Neurosurgery* 2003;98(1):21-30.

Georgy BA. Bone cement deposition patterns with plasma-mediated radio-frequency ablation and cement augmentation for advanced metastatic spine lesions. *Am J Neuroradiol* 2009;30(6):1197-1202.

Lamacraft G, Cousins MJ. Neural blockade in chronic and cancer pain. *Int Anesthesiol Clin* 1997;35(2):131-53

Hentschel SJ, Burton AW, Fourney DR, Rhines LD, Mendel E. Percutaneous vertebroplasty and kyphoplasty performed at a cancer center: refuting proposed contraindications. *J Neurosurgery (Spine)* 2005;2(4):436-40.

Mercadante S. Intrathecal morphine and bupivacaine in advanced cancer pain patients implanted at home. *J Pain Symptom Manage* 1994;9(3):201-7.

Mercadante S, Villari P, Cascuccio, Marrazzo A. A randomized-controlled study of intrathecal versus epidural thoracic analgesia in patients undergoing abdominal cancer surgery. *J Clin Monit Comput* 2008;22(4):293-8.

Mishra S, Bhatnagar S, Gupta D, Thulkar S. Anterior ultrasound-guided superior hypogastric plexus neurolysis in pelvic cancer pain. *Anaesth Intensive Care* 2008; 36(5):732-5.

Moore JC, Adler DG. Celiac plexus neurolysis for pain relief in pancreatic cancer. *J Support Oncol* 2009;7(3)83-7.

Munk PL, Rashid F, Heran MK, et al. Combined cementoplasty and radiofrequency ablation in the treatment of painful neoplastic lesions of bone. *J Vasc Interv Radiol* 2009;20(7):903-11.

Pausch R, Zaslow. *The Last Lecture*. Hyperion Publishers, New York, New York, 2008.

Plancarte R, deLeon-Casasola OA, El-Helaly M, Allende S, Lema MJ. Neurolytic superior hypogastric plexus block for chronic pelvic pain associated with cancer. *Reg Anesth* 1997;22(6):562-8.

---

# ANESTHESIOLOGY 2012

---

TRANSFORMING PATIENT SAFETY THROUGH EDUCATION AND ADVOCACY

Phan PC, Are M, Burton AW. Neuraxial infusions. *Techniques in Regional Anesthesia and Pain Management*. 2005; 9(3):152-160.

Raslan AM. Percutaneous computed tomography-guided radiofrequency ablation of upper spinal cord pain pathways for cancer-related pain. *Neurosurgery* 2008;62(S1):226-33.

Rathmell JP. *Atlas of Image Guided Intervention in Regional Anesthesia and Pain Medicine*. Lippincott Williams & Wilkins, Philadelphia PA, 2006.

Rauck RL, Wallace MS, Burton AW, Kapural L, North JM. Intrathecal ziconotide for neuropathic pain: a review. *Pain Practice*. 2009; 9(5):327-37.

Schultz DM. Inferior hypogastric plexus blockade: a transsacral approach. *Pain Physician* 2007;10(6):757-63.

Sharma P and Kozarek R. Role of esophageal stents in benign and malignant disease. *Am J Gastroenterol* 2009 e pub.

Slatkin NE, Rhiner M. Phenol saddle blocks for intractable pain at the end of life: report of four cases and literature review. *Am J Hosp Palliat Care* 2003;20(1):62-6.

Smith TJ, Staats PS, Deer T, et al. Randomised clinical trial of an implantable drug delivery system compared with comprehensive medical management for refractory cancer pain; impact on pain, drug related toxicity and survival. *J Clin Oncol* 2002;20:4040-9.

Smith TJ and Coyne PJ. How to use implantable intrathecal drug delivery systems for refractory cancer pain. *J Support Oncol* 2003;1(1):73-6.

Smith TJ, Coyne PJ, Staats PS, et al. An implantable drug delivery system for refractory cancer pain provides sustained pain control, less drug related toxicity and possibly better survival compared to comprehensive medical management. *J Clin Oncol* 2005;16:825-833.

Swarm R, Angheliescu DL, Benedetti C, et al. Adult cancer pain. *J Natl Compr Canc Netw* 2007;5(8):726-51.

Varghese BT, Koshy RC, Sebastian P, Joseph E. Combined sphenopalatine ganglion and mandibular nerve, neurolytic block for pain due to advanced head and neck cancer. *Palliat Med* 2002;16(5):447-8.

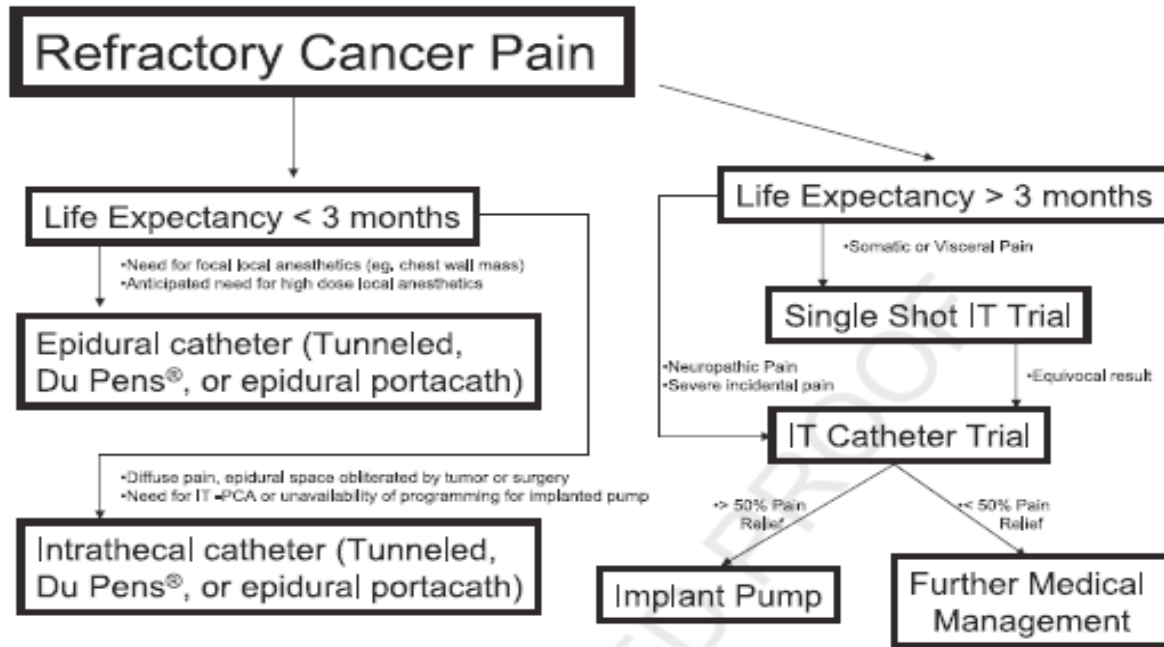
Vila H, Liu J, Kavasmaneck D. Paravertebral block: new benefits from an old procedure. *Curr Opin Anaesthesiol* 2007;20(4):316-8.

Wong FCS, Lee TW, Yuen KK, Lo SH, Sze WK, Tung SY. Intercostal nerve block for cancer pain: effectiveness and selection of patients. *Hong Kong Medical Journal* 2007; 13:266-70.

# ANESTHESIOLOGY 2012

TRANSFORMING PATIENT SAFETY THROUGH EDUCATION AND ADVOCACY

Figure 1. Decision making for neuraxial infusions in refractory cancer pain. (Phan 2005)



## DISCLOSURE

Medtronic, Self, Consulting Fees ; Boston Scientific, Self, Consulting Fees ; Stryker, Self, Consulting Fees ; Azur, Self, Honoraria ; Cadence, Self, Honoraria ; Cephalon, Self, Honoraria ; Neurogesx, Self, Honoraria ; Pfizer, Self, Honoraria ; Pricara, Self, Honoraria ; Vapo